

Protective Effect of Gingo biloba Extract and Artichoke Extract against Hypatocytes Carcinoma in Male Rats

Hala M. A. Wahba

Home Economics Department, Faculty
of Specific Education, Minufiya
University

Abstract:

This study aimed to evaluate the protective effect of Gingo biloba Extract and Artichoke Extract against hepatocarcinoma induced by tetrachloro carbon (CCL₄) in rats. Thirty male rats were distributed into 5 equal groups. Group 1 was negative control and the other 4 groups were intoxicated by a single intraperitoneal dose (0.2 ml/100g /b.w) of CCL₄ for 30 days to induce hepatocarcinoma. Group 2 was kept positive (intoxicated) control and groups 3, 4 and 5 were orally given Ginkgo biloba L, (Ginkgoaceae) (EGB761), 20% Artichoke extracts and mix of them for 8 weeks, respectively. The study showed that treatment with CCL₄ caused high significant decrease in the content of high density lipoprotein (HDL) , total proteins, globulin and albumin and significant increase in the (LDL), Lipid peroxidation, the collagen content, red blood cells count (R.B.Cs) and white blood cells count (W.B.Cs), blood platelets and the haematocrit. Oral administration of (EGB761) , 20% Artichoke extracts and mix of them inhibited elevations in serum biochemical aspartate aminotransferase (AST), alanine aminotransferase(ALT), (LDL) , lipid peroxidation and total in tumor biomarkers (alpha fetoprotein, tumor necrosis factor-alpha and nuclear factor-kappa beta) and induced levels increased the content of (HDL), blood platelets, the haematocrit, content of collagen during the period of treatment up to 60 days . The protective mechanism of action might be due to inhibition of hepatic lipid peroxidation, lowering oxidative stress and induction of apoptosis.

Keywords: Ginkgo biloba, Artichoke, Hepatocarcinoma, Lipid peroxidation

INTRODUCTION

vonoids, and polyphenols that can protect the liver against damages induced by hepatotoxic drugs (Galisteo *et al.*, 2000). Medicinal plants play an important role in pharmacology and medicine for hundreds years. Leaves of the plant Ginkgo biloba have been used for thousands of years as a traditional Chinese herbal medicine . Ginkgo trees are now widely planted in China, Japan, Korea, France, Germany and the United States for both ornamental and medicinal purposes. G. biloba extract is believed to provide beneficial effects in memory impairment, stroke, edema, inflammation, Alzheimer's dementia, and vasoconstrictive disorders. A standardized chemical product (761, EGB) from these leaves was pharmacologically prepared containing two major functional constituents (24% - 25% flavonoid glycosides and 6% terpenoids) (Diamond *et al.*, 2000). Globe artichokes have been touted as a healthy food for centuries. They were commonly used as a medicinal food by the ancient Egyptians and Romans, being thought to aid digestion and protect the liver. There have been several *in vitro* studies showing that artichoke leaf extracts do indeed perform the functions our ancient ancestors believed they did. Llorach *et al.*, (2002) and Wang *et al.*, (2003) showed that artichoke leaf extract protects the liver, is antibacterial, choleric, urinate as well as anti-HIV. In fact, owing to its lower costs and greater compatibility, herbal medicine has received a great attention in recent decades (Azadbakht *et al.*, 2003). *Ginkgo biloba*, a unique tree, is one of the best known examples of a living fossil. Ginkgo leaf extract has powerful anti-cancer properties through its antioxidant, gene-regulatory and antiangiogenic properties Yang *et al.*, (2005).

Ginkgo biloba extract may regulate cell proliferation and induce apoptosis of human hepatocellular cell lines: HepG2, Hep3B, and SMMC-7721 cells, therefore it may have protective effects against hepatocarcinogenesis Mahadevan and Park (2008). The therapeutic mechanisms of action of Ginkgo leaf extract are suggested to be through its antioxidant, antiplatelet, antihypoxic, antiedemic, hemorrheologic and microcirculatory actions, where the flavonoid and terpenoid constituents may act in a complementary manner Qi *et al.*, (2010) . Artichoke leaves are rich in polyphenolic compounds, inulin, fibre and minerals. It also helps mineral absorption, including potassium and sodium, as well as vitamin C. Blood lipid composition and the prevention of colon cancer (Lattanzio *et al.*, 2009) . Chronic

liver diseases are major global health problems causing approximately 800,000 deaths per year worldwide. The Egyptian population has a heavy burden of liver disease, mostly due to chronic infection with hepatitis C virus (*Kurbanov et al., 2010*), alcoholism, virus-induced chronic liver disease, and using hepatotoxic drugs (antibiotics, carbon tetrachloride, thioacetamide, and acetaminophen) are the major risk factors for liver diseases (Saleem et al., 2010). Liver is a vital organ that plays a role in controlling critical biochemical and physiological activities including homeostasis, growth, energy and nutrient supply, detoxification of drugs and other xenobiotics, and also combating infections (*Olorunnisola et al., 2011*). Thioacetamide (TAA) is a typical hepatotoxin, causing centrilobular necrosis. It induces apoptosis in the rat liver based on Medicinal plants have been used from ancient times for the treatment of a wide variety of diseases (*Khosravi-Boroujeni et al., 2012*) as well as for hepatotoxicity (*Heidarian and Rafieian-Kopaei, 2013*). Artichoke also appears to help lower blood pressure and antioxidant activity was found in coronary artery smooth muscle cells by (*Ceccarelli et al 2010*).

MATERIALS and METHODS

a- Materials

- 1- Food items: The studied materials consisted of Artichoke (*Cynara scolymus, L.*) all food items have been bought (from local market at Minufiya Governorate) fresh and prepared for use. Ginkgo biloba L. (*Ginkgoaceae*) *Ginkgo biloba* extract used as Tanakan (EGB 761) produced by Amriya for Pharmaceutical Industries, Egypt under license of Beaufour- ipsis International, Paris-France according to the method described by (*He et al., 2006 Liu et al., 2006 and Zhang et al., 2006*).
- 2- Carbon tetrachloride (CCL₄) : Pure liquid chemical fine (obtained from Sigma) was used for inducing hepatitis in this study. Untreated rats are referred to as the control negative (control-group).
- 3- Preparation of plant extracts :
 - a-Sample (200 g) of sample of Artichoke (*Cynara scolymus, L.*) group (4) + 1000 ml distilled water, were kept in conical flasks provided with glass condensers then boiled for one hour to obtain the extracts.
 - b – The boiled mixture was coded and filtered.

c - The filtrate poured in different petri dishes and dried under vacuum

at 70 ° c to dried powder. The powder has been dissolved in certain amount of distilled water. The amount of solution equivalent to 20 % Artichoke extracts was administered orally using a tube.

Methods:

1- Biological Investigation:

Male albino rats Sprague Dawley strain (30 rats) weighing 185.5 ± 2.5 g were obtained from Helwan experimental animal station. All rats were housed individually in well-aerated cages and fed on basal diet for one week for adaptation, animal house of Faculty of Home Economics, Minufiya University.

The basal diet consists of casein (12.5%), corn oil (10%), choline chloride (0.2%), vitamin mixture (1%) (Campbell, 1963), cellulose (5%), salt mixture (4%), sucrose (22%) and corn starch (up to 100%) (Hegsted et al., 1941).

2- Preparation of hepatitis rats

Normal healthy adult male albino rats were injection by Carbon tetrachloride (CCL4) twice weekly for two weeks (0.2 mg/100g) body weight according to the method described by (Lin and Lin, 2006) then investigated level of Got and GPT by random select to any rat to obtained sample blood serum, after positivism form infect rats were divided into 4 groups .

3- Experimental Design:

The rats were divided into two main groups, the first main group (6 rats) fed on basal diet as a negative control **Group (1): Non hepatitis control control (-)**.

. The second main group (24 **hepatitis** rats) were divided into four groups (n=6) according to the following scheme:

Groups::

- 1- control group (control (+) fed on basal diet.
- 2- **hepatitis** rats fed on basal diet +Ginkgo biloba L, (Ginkgoaceae), (EGB761) at a dose level of 260 mg/kg body weight for 60 days.
- 3- **hepatitis** rats fed on basal diet +20% Artichoke extracts for 60 consecutive days.
- 4- **hepatitis** rats fed on basal diet+ mix of them (20% Artichoke extracts + Ginkgo biloba extracts for 60 consecutive days.

5- During the experimental period (60 days), the diet consumed was recorded every day, body weight was recorded every week. At the end of the experimental period, rats were fasted overnight before sacrificing. Blood sample were collected from aorta, in dry clean centrifuge tube, and left for 15 minutes to clot at room temperature, then centrifuged for a 15 minutes at 3000 rpm to separate serum. Liver was removed, cleaned and weighted.

5- Biological Evaluation:

All rats were weighted once weekly. At the end of the experiment, biological evaluation of the different diets was carried out by determination of body weight gain % (BWG %), food efficiency ratio (FER) according to **Chapman *et al.*, (1959)**.

6- Analytical methods:

Enzymatic colorimetric method used to determine blood glucose according to **Trinder (1969)**. Colorimetric method was used for the determination of total cholesterol according to **Allain (1974)**. Determination of HDLc was carried out according to the method of **Fnedewaid (1972)** and **Gordon and Amer (1977)**. Enzymatic colorimetric method used to determine triglycerides according to Young and Pestaner (1975). The determinations of LDLc were carried out according to the method of Lee and Nieman (1996) as .Colorimetric method used to determine AST and ALT according to Reitman and Frankel (1957); while determination of alkaline phosphates ALP activity according to (Roy, 1970). Deremination of serum lipid peroxidation products according to (Ohkawa et al.,1979). Determination of serum total protein according to (Glick et al.,1986):Determination of serum albmin according to (Doumas et al., 1972) Determination of content serum Collagen according to (Lopez de Leon and Rojkind .,1985). Determination of Serum Interferon gama (INF- γ), Tumer necrosis factor alpha (TNF α) according to Stanilov *et al.* (2010). Determination of Serum Immunoglobulin (IgG) (Ellezam et al, 2003 and Tucker et al., 2003). Determination of liver Superoxide dismutase (SOD) activity (Nishikimi et al., 1972) •Determination of serum catalase (CAT) activity according to (Aebi. 1993). Determination of liver adenosine triphospatase (ATPase) activity Modified by EL-Aser and EL- Mersabani (1975). Determination of serum Lactate dehydrogenase (LDH) actifity according to (Martinek ,1972). Determination of the activity of glutathione S-transferase (GST) in the serum according to (Habig *et al.*, 1974). Determination of Liver

Glutathione (GSH) content according to (Beutler, 1975 & Prins and Loose, 1969).

7- Histopathological study

Liver specimens only were collected from rats of all experimental groups at the end of the experimental period, fixed in 10% neutral buffered formalin (pH=7.0), dehydrated in ethyl alcohol, then cleared in xylol and embedded in paraffin; 4-6 microns thickness sections prepared and stained with hematoxylin and eosin for examining the liver using light microscope at various magnification (Carleton, 1976).

8-Statistical Analysis

Statistical analysis performed by using computer program statistical package for social science (SPSS, 2008), and values compared with each other using the suitable tests.

RESULTS :

Intraperitoneal injection of CCL4 in rats significantly elevated serum levels of Serum Interferon Gama (INF- جاما), tumor necrosis factor-alpha (TNF- α), and Serum Immunoglobulin (IgG) when compared with the positive control group. Oral administration of (EGb 761), Artichoke and mix of them concentrations daily for 8 weeks significantly lowered the elevated serum INF-, TNF- α and (IgG) levels when compared to the positive group as recorded in table (1 and 2).

Rats intoxicated with CCL4 had significant increase in Liver superoxide dismutase (SOD) and Serum Catalase (CAT) but an decreases in Adenosine Triphosphate (ATP ase) levels when compared with the negative control group. administration of (EGb 761), Artichoke and mix of them concentrations daily for 8 weeks significantly normalized serum levels of (SOD), (CAT) and (ATP ase) when compared to the positive control group as depicted in table (3).

Single intraperitoneal injection of CCL4 (.2ml/kg b.wt) in rats significantly increased serum levels of liver enzymes aspartate amino transferase (AST) and alanine amino-transferase (ATL) when compared with the negative control rats, indicating incidence of liver damage and exit of enzymes into circulation. Oral administration of (EGb 761), Artichoke and mix of them concentrations daily for 8 weeks significantly lowered the elevated serum AST and ALT levels when compared to the positive control group as recorded in table (5).

Rats intoxicated by CCL4 had significant high content of Glutathion -s-Transferase (GSTS) and low content of reduced glutathione (GSH) when compared with the negative control group. Oral administration of

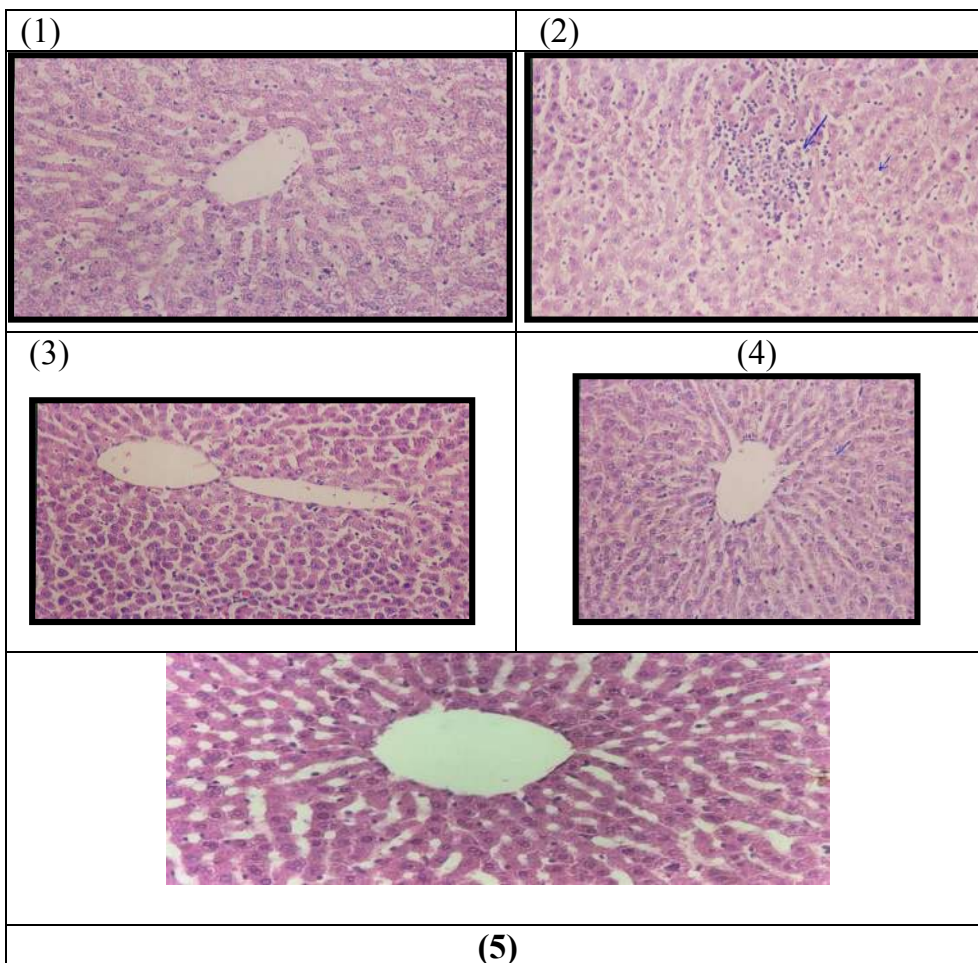
(EGb 761) , Artichoke and mix of them concentrations significantly normalized hepatic contents of (GSTS) and GSH when compared to the positive control group, as depicted in table (6).

In rats intoxicated with Total cholesterol, Triglycerides and LDL by CCL4, was elevated to compared to the negative control group. Oral administration of (EGb 761) , Artichoke and mix of them concentrations significantly reduced the high content of Total cholesterol, Triglycerides and LDL respectively in the positive control group as depicted in table (8).

Activities of Serum total protein, Albumin and Globulin in rats intoxicated with CCL4 were significantly decreases as compared with the negative control group. Oral administration of (EGb 761) , Artichoke and mix of them concentrations significantly enhanced the activity of Serum total protein, Albumin and Globulin when compared with the positive control group as recorded in table (9).

Rats intoxicated by CCL4 had significant decreases content of Blood Erythrocytes (R.B.Cs), Blood Leukocytes(W.B.Cs) and Blood Platelets (PLT) when compared with the negative control group. Oral administration of (EGb 761) , Artichoke and mix of them concentrations significantly increase contents of Blood Erythrocytes (R.B.Cs), Blood Leukocytes(W.B.Cs) and Blood Platelets (PLT) when compared to the positive control group, as depicted in table (11).

Histopathological examination of liver sections of rats in negative control group showed normal histological structure of hepatic lobule with normal hepatocytes, portal vein and sinusoids (Fig.1). Liver sections of rats intoxicated with CCL4 showed trabecular hepatocellular carcinoma (long arrow) with fat droplets (short arrow) in tumor cells (Fig. 2). Polymorphism of nuclei of hepatocytes (arrows) was seen as shown in Fig. (3). Oral administration of large (20%) concentration Artichoke caused regression of preneoplastic lesions induced by CCL4 and presence only of mild fat droplets was seen (Fig.4). Examination of liver sections of rats given the large mix of them showed amelioration of preneoplastic lesions as shown in Fig.(5)



Legend of Figures:

Fig. (1): C.S. of liver of a negative control rat showing normal histological structure of hepatic lobule with normal central vein, hepatocytes and sinusoids. (H&E X 200).

Fig. (2): C.S. of liver of a rat injected with CCL4 showing trabecular hepatocarcinoma (long arrow) with fat droplets (short arrow) in tumor cells. (H&E X 200).

Fig. (3): C.S. of liver of a rat injected with CCL4 with (EGb 761) showing polymorphism of nuclei of hepatocytes (arrows). (H&E X 400)

Fig. (4): C.S. of liver of a rat given large (20%) concentration of Artichoke

showing regression of preneoplastic lesions induced by CCL4 and presence only of mild fat droplets. (H&E X 200).

Fig. (5): C.S. of liver of a rat given large concentration mix of them showing amelioration of preneoplastic lesions induced by CCL4. (H&E X 200).

Table (1) : Serum Interferon Gama (INF- γ) and Immunocytokine (Tumor necrosis factor alpha (TNF- α) content (pg/ml) in the control and different treated groups of adult male rats.

	Experimental Animals				
	Control (-)	Control (+)	Treated Animals		
	Mean \pm S.E.	Mean \pm S.E.	(EGb 761)	Artichoke	Mix
(INF- γ) (pg/ml)	12.04 \pm 0.35	56.20 \pm 1.23	18.06 \pm 0.36**	36.67 \pm 0.59	33.40 \pm 0.38*
(TNF- α) (pg/ml)	11.37 \pm 0.33	126.93 \pm 3.31**	15.77 \pm 0.58	108.74 \pm 3.79	55.35 \pm 0.88**

Number of Animals: 6

* Significant

** Highly Significant

Table (2) : Serum Immunoglobulin (IgG) content (μ g/L) in the control and different treated group of adult male rats.

	Experimental Animals				
	Control (-)	Control (+)	Treated Animals		
	Mean \pm S.E.	Mean \pm S.E.	(EGb 761)	Artichoke	Mix
(IgG) (μ g/L)	13.60 \pm 0.42	39.18 \pm 0.75	18.24 \pm 0.70*	35.15 \pm 0.67	32.30 \pm 0.78**

Number of Animals: 6

* Significant

** Highly Significant

Table (3): Liver Superoxide Dismutase (SOD) activity (U/g) fresh tissue , Adenosine Triphosphatease (ATPase) activity of the liver (μ mol pi/ min/ g fresh tissue) and Serum Catalase (CAT) activity (U/L) in the control and different treated groups of adult male rats.

	Experimental Animals				
	Control (-)	Control (+)	Treated Animals		
	Mean \pm S.E.	Mean \pm S.E.	(EGb 761)	Artichoke	Mix
(SOD) (U/g)	53.11 \pm 0.75	18.07 \pm 0.72	58.49 \pm 0.57	35.96 \pm 0.40	49.71 \pm 0.61 **
(ATP)	2.62 \pm 0.31	5.45 \pm 0.34	5.61 \pm 0.23	4.34 \pm 0.20*	4.81 \pm 0.18
(CAT) (U/L)	31.19 \pm 0.15	13.27 \pm 0.25	35.50 \pm 0.21	22.92 \pm 0.32	26.45 \pm 0.26 *

Number of Animals: 6

* Significant

** Highly Significant

Table (4): Serum Lactic Dilydrogenase (LDH) activity (U/L) in the control and different treated groups of adult male rats.

	Experimental Animals				
	Control (-)	Control (+)	Treated Animals		
	Mean \pm S.E.	Mean \pm S.E.	(EGb 761)	Artichoke	Mix
(LDH) (U/L)	1574.50 \pm 22.99	5371.83 \pm 171.99**	1517.67 \pm 35.14	2597.33 \pm 57.01**	1860.67 \pm 24.87*

Number of Animals: 6

* Significant

** Highly Significant

Table (5): Serum Aspartate Amino Transferase (AST) and Alanin Amino Transferase (ALT) activity (U/L) in the control and different treated groups of adult male rats.

	Experimental Animals				
	Control (-)	Control (+)	Treated Animals		
	Mean ± S.E.	Mean ± S.E.	(EGb 761)	Artichoke	Mix
(AST) (U/L)	307.67 ±5.10	892.33 ±20.36**	331.17 ±15.19	575.50 ±32.25	436.33 ±12.96**
(ALT) (U/L)	69.13 ±1.16	778.50 ±3.20	78.33 ±1.08	392.50 ±1.12*	145.17 ±1.11**

Number of Animals: 6

* Significant

** Highly Significant

Table (6): Glutathion-S-Transferase (GSTS) level of the serum (U/L) and Glutathione (GSH) content of the liver (mg/g) fresh tissue in the control and different treated groups of adult male rats.

	Experimental Animals				
	Control (-)	Control (+)	Treated Animals		
	Mean ± S.E.	Mean ± S.E.	(EGb 761)	Artichoke	Mix
(GSTS) (U/L)	255.81 ±1.39	331.73 ±17.08	199.13 ±0.56	287.42 ±3.75	246.38 ±10.33**
(GSH) (mg/g)	385.18 ±16.01	94.72 ±1.44	349.74 ±9.63	174.08 ±4.35	293.94 ±18.32

Number of Animals: 6

* Significant

** Highly Significant

Table (7): Liver total lipids (mg/g wet tissue) Liver Triglycerides and total Liver cholesterol (m mol/L) content in the control and different treated groups of adult male rats.

	Experimental Animals				
	Control (-)	Control (+)	Treated Animals		
	Mean ± S.E.	Mean ± S.E.	(EGb 761)	Artichoke	Mix
total lipids Liver	62.80 ±1.42	80.32 ±0.89	64.00 ±0.59	73.55 ±1.82	64.60 ±0.93**
Liver Triglycerides (m mol/L))	1.63 ±0.06	0.85 ±0.05	1.82 ±0.04	1.13 ±0.03*	1.70 ±0.04
Liver total cholesterol	1.33 ±0.04	0.31 ±0.03	1.00 ±0.07	0.89 ±0.05	1.13 ±0.05*

Number of Animals: 6

* Significant

** Highly Significant

Table (8): Serum total cholesterol , Triglycerides, High density lipoprotein and low density lipoprotein in content (m mol/L) in the control and different treated groups of adult male rats.

	Experimental Animals				
	Control (-)	Control (+)	Treated Animals		
	Mean ± S.E.	Mean ± S.E.	(EGb 761)	Artichoke	Mix
total cholesterol	1.31 ±0.04	2.31 ±0.07	1.21±0.03	2.09 ±0.05	1.38 ±0.03*
Triglycerides (m mol/L)	1.45 ±0.05	2.28 ±0.05	1.26±0.03	1.98 ±0.03	1.71 ±0.03*
HDL	0.99 ±0.11	0.46 ±0.07	0.98±0.08*	0.75 ±0.11	0.98 ±0.09**
LDL	1.3 ±0.02	2.89 ±0.13	1.36±0.03	2.01 ±0.16	1.55 ±0.16*

Number of Animals: 6

* Significant

** Highly Significant

Table (9): Serum total proteins (g/L), Albumin (g/L) ,Globulin (g/l), and Collagen content (µ g/ mg prot) in the control and different treated groups of adult male rats

	Experimental Animals				
	Control (-)	Control (+)	Treated Animals		
	Mean □ S.E.	Mean □ S.E.	(EGb 761)	Artichoke	Mix
total proteins	64.17 □1.08	44.83 □0.65	71.50□0.43	57.83 □0.40	62.00 □0.52*
Serum Albumin	46.17 □0.31	32.67 □0.21	45.17□0.31	40.83 □0.31**	43.50 □0.33
Serum Globulin	20.17 □0.31	9.50 □0.72	21.83□0.48	18.00 □0.26	19.67 □0.41*
Serum Collagen	20.20 □0.17	64.73 □0.44	22.55□0.40	44.50 □1.07*	32.16 □0.73

Number of Animals: 6

* Significant

** Highly Significant

Table (10): Serum glucose level (m mol/ L) in the control and different treated groups of adult male rats.

	Experimental Animals				
	Control (-)	Control (+)	Treated Animals		
	Mean □ S.E.	Mean □ S.E.	(EGb 761)	Artichoke	Mix
Glucose	8.75 □0.20	9.30□0.12	10.30 □0.25	8.18 □0.24*	8.85 □0.22

Number of Animals: 6

* Significant

** Highly Significant

Table (11): Blood Erythrocytes (R.B.Cs), Blood Leukocytes (W.B.Cs) and Blood Platelets (PLT) ($\times 10^6/\mu\text{L}$) count in the control and different treated groups of adult male rats.

	Experimental Animals				
	Control (-)	Control (+)	Treated Animals		
	Mean □ S.E.	Mean □ S.E.	(EGb 761)	Artichoke	Mix
(R.B.Cs)	8.46 □ 0.01	7.28 □ 0.21	8.29 □ 0.03	7.87 □ 0.02*	8.14 □ 0.06
(W.B.Cs)	13.97 □ 0.06	8.23 □ 0.13	13.28 □ 0.06	9.85 □ 0.26**	11.60 □ 0.34
(PLT)	643.00 □ 0.58	297.00 □ 5.97	444.33 □ 10.94	783.50 □ 11.33	709.83 □ 7.05**

Number of Animals: 6

* Significant

** Highly Significant

Table (12): Blood Hemoglobin (Hgb) (g/100 ml) and Blood Haematocrite percentage (HCT) in the control and different treated groups of adult male rats.

	Experimental Animals				
	Control (-)	Control (+)	Treated Animals		
	Mean □ S.E.	Mean □ S.E.	(EGb 761)	Artichoke	Mix
(Hgb) (g/100 ml)	16.25 □ 0.19	14.03 □ 0.23	15.53 □ 0.15	14.30 □ 0.14	15.15 □ 0.11*
(HCT)	45.63 □ 0.20	39.38 □ 0.10	44.85 □ 0.23	41.82 □ 0.25**	43.22 □ 0.09*

Number of Animals: 6

* Significant

** Highly Significant

DISCUSSION

There is a great need to search for much safe natural materials to be developed for the prevention and therapy of hepatocarcinoma. Fruits and vegetables with anticancer activity have gained much attention (Brown, 2012). The biological value of the plant materials depends on presence of bioactive constituents, especially those of antioxidant properties. The mechanisms underlying the anticancer activity of plant materials are still need for further investigations. Therefore, the aim of the present study was to evaluate the protective effect and to examine the possible mechanisms of action of (EGb 761), Artichoke and mix

of them against hepatocarcinoma induced by CCL4 in rats. Carbon tetrachloride (CCl4) is a selective hepatotoxic chemical agent that commonly used for induction of hepatitis in rats (Li *et al.*, 2013). CCl4 produces reactive free radicals (trichloromethyl radical, CCl3) which initiate cell damage via either covalent binding to cell membrane proteins or by induction of lipid peroxidation. Lipid peroxidation is associated with hepatic cell damage and leads to liver cirrhosis and fibrosis (Barrera, 2012). In this study, intoxication of rats by CCL4, induced hepatocellular carcinoma manifested by high serum levels of liver enzymes aspartate amino transferase (AST) and alanine amino-transferase (ATL) when compared with the negative control rats. The serum and tissue biochemical alterations were parallel to preneoplastic lesions seen upon histopathological examination of liver sections. These results were similar to the previous reports by Sundraresan and Subramanian (2008) and Zhang *et al.*, (2012). The previous authors concluded that intoxication of rats with CCL4 induces hepatocellular carcinoma characterized by nearly similar serum and tissue biochemical alterations as well as histopathological hepatic precancerous lesions that reported in this study. The present results revealed that oral administration (EGb 761) , Artichoke and mix of them rats intoxicated by CCL4 exhibited an anticancer activity against hepatocarcinoma. This activity was manifested by restoration of serum liver enzymes to nearly normal levels; inhibition of lipid peroxidation and oxidative stress as well as regression of biomarkers of hepatocarcinoma. These findings agreed with the previous reports by **Mahboub and Hawazen**,(2013),The previous authors concluded that EGB can improve the hepatotoxicity of carbendazim and this effect may be attributed to antioxidant properties of *Ginko biloba* extract. Medicinal plants play an important role in pharmacology and medicine for hundreds years. Leaves of the plant *Ginko biloba* have been used for thousands of years as a traditional Chinese herbal medicine Logani,*etal.*, (2013).*Ginkgo* trees are now widely planted in China, Japan, Korea, France, Germany and the United States for both ornamental and medicinal purposes. The therapeutic mechanisms of action of Ginkgo leaf extract are suggested to be through its anti-oxidant, antiplatelet, antihypoxic, antiedemic, hemorrhheologic and microcirculatory actions, where the flavonoid and terpenoid constituents may act in a complementary manner (Mahadevan and Park ,2008)and (Qi,*etal.*,2010) Recently, Al-Attar, 2012 reported that *G. biloba* leaves extract inhibits liver fibrosis induced by thioacetamide in mice. The present study was designed to evaluate the protective effect of *G. biloba* leaves extract on hepatotoxicity of carbendazim in albino rats. A standardized chemical product (761, EGB) from these leaves was pharmacologically prepared containing two major functional constituents (24% - 25% flavonoid glycosides and 6% terpenoids) Shen,*et al.*,(1998). This extract was found to have many pharmacol-

ological proposes. It has neuroprotective, anticancer, cardioprotective, stress alleviating, memory enhancing effects and possible effects on tinnitus and psychiatric disorders Masteikova, *etal.*, (2007)

Artichoke extract is one of the few herbal remedies where the clinical and experimental trials have complemented each other. Both experimental and clinical effects have been verified through extensive biomedical herbal remedy research. Specifically, antioxidant, choleric, hepatoprotective, bile-enhancing and lipid-lowering effects have been demonstrated, which

correspond with its historical use (Yerram, 2011) The use of the artichoke plant as food in many countries over hundreds of years supports its safety. typically contain 3% caffeoylquinic acids, this new artichoke extract is standardized to contain 15% caffeoylquinic acids, calculated as chlorogenic acid. Artichoke has been used in traditional medicine for centuries as a specific liver and gallbladder remedy. Globe artichokes have been touted as a healthy food for centuries. They were commonly used as a medicinal food by the ancient Egyptians and Romans, being thought to aid digestion and protect the liver . (Lattanzio *et al.*, 2009) showed that artichoke leaf extract protects the liver, antibacterial, choleric, urinate as well as anti-HIV. Artichoke leaves are rich in polyphenolic compounds, inulin, fibre and minerals , It also helps mineral absorption, blood lipid composition and the prevention of colon cancer. In conclusion, the results denote that oral administration of EGb 761 and 20 % Artichoke extract protective effect against hepatocarcinoma. The mechanisms underlying this activity might be due to inhibition of lipid peroxidation, lowering oxidative stress and induction of apoptosis. These results confirm the traditional use of of EGb 761 and 20 % Artichoke extract in folk medicine for the treatment of many types of cancers such as liver, lung, stomach and breast cancers. The study recommends that intake of (EGb 761) , Artichoke and mix of them as a drink may be useful for patients who suffer from hepatocarcinoma due to oxidative stress .

REFERENCES :

- 1- Aebi, H. (1993):Catalase. In: Bergmeyer, H.U. (Ed.), Methods in enzymatic analysis, Vol. 3, Academic Press, New York, pp. 276-286.
- 2- Allain , C.C. (1974) : Cholesterol enzymatic colorimetric method .J. of Clin . Chem ., (20) : 470 .
- 3- Azadbakht, M. ; ZIAI, H. ; Abdollahin, F. and Shabankhani, B.(2003): Effect of essential oils of *Artemisia aucheri* Bioss., *Zataria multiflora* Boiss and *Myrtus communis* L. on *Trichomonas vaginalis*. Iran J.Pharmaceut. Res., 2: 35-40.
- 4- Al-Attar, M. A. (2012):“Attenuating Effect of Ginkgo biloba Leaves Extract on Liver Fibrosis Induced by Thioacet- amide in Mice,” Journal of Biomedicine and Biotechnol- ogy, Vol, Article ID: 761450. doi:10.1155/2012/761450
- 5- Beutler E. (1975): Glutathione in red blood cell metabolism. A Manual of Biochemical Methods, Grune & Stratton, *New York*:112-114.
- 6- Carleton, H. (1976): Carleton's Histological technique. 4th Edition, London, Oxford University press New York, Toronto.
- 7- Campbell, J.A. (1963): Methodology of Protein Evaluation . RAG Nutr., Document R.10, Led . 37. June Meeting, New york .
- 8- Chapman, D.G; Castilla , R. and Campbell, J. A. (1959) : Evaluation of protein in food I : A method for the determination of protein efficiency ratio . Can . J. Biochem . Physiol., 37 : 679 – 686 .
- 9- Ceccarelli, N. ; Curadi, M. ; Picciarelli, P. ; Martelloni, L. ; Sbrana, C. & Giovannetti, M. (2010): Globe artichoke as functional food. *Mediterr. J. Nutr. Metab.*, 3, 197-201.
- 10- Diamond, S. S. ; hiflett, N. ; Feiwel, R. J. ; Matheis, O. ; Noskin, J. A. Richards , B. J.and Schoenberger, N. E.(2000) : “*Gin-ngo biloba* Extract: Mechanisms and Clinical Indications,” *Archives of Physical Medicine and Rehabilitation*, Vol. 81, No. 5, pp. 668-678.
- 11- Doumas, B. ; Homer , G. and Robert, L. (1972): Determination of serum albumin . In standard methods of clinical chemistry . Acad . press . N . Y . , 7 : 175-177 .
- 12- Ellezam, B., Bertrand, J., Dergham, P. and McKerracher, L. (2003): Vaccination stimulates retinal ganglion cell regeneration in the adult optic nerve. *Neurobiology of Disease*, 12(1): 1-10.
- 13- Fnedewaid, W.T. (1972) :Determination of HDL. Clin. Chem.,18 : 499.
- 14- Galisteo, M. ; Suarez , A. ; Montilla, M. P., ; Utrilla, M. D. ; Jimenez, J., Gil, A. ; Faus, M. and Navarro, M.D.(2000). Antihepatotoxic activity of *Rosmarinus tomentosus* in a model of acute hepatic damage induced by thioacetamid. *Phytother. Res.*, 14: 522–526.

- 15- Gordon, T. and Amer, M. (1977) : Determination of HDL . J. Med., 62 : 707
- 16- Glick MR, Ryder KW, Jackson SA. (1986): Graphical comparisons of interferences in clinical chemistry instrumentation. Clin Chem; 32: 470-8474.
- 17- Hegsted, A. (1941): Salt mixture. J. Biol. Chem., 138: 459.
- 18- Habig, W.H. ;Pabst, M.J. and Jakoby, W.B. (1974) : Glutathione Stransferases.The first enzymatic step in mercapturic acid formation, J. Biol. Chem. 249 ;7130–7139.
- 19- He, S.X .; Luo, J.Y. ; Wang , Y.P.; Wang, Y.L;Fu, H. ; Xu, J.L; Zhao, G.and Liu, E.Q. (2006) :Effects of extract from *Ginkgo biloba* on carbon tetrachloride-induced liver injury in rats. World J Gastroenterol. 28;12 (224): 3924-8.
- 20- Heidarian, E. and Rafieiafieian -KOPAEI, M.(2013):.Protective effect of artichoke (*Cynara scolymus*) leaf extract against lead toxicity in rat. *Pharmacol. Biol.*, 51:1104-1109.
- 21- Kurbanov , F. ;Tanaka, Y. and Mizokami, M.(2010): Geographical and genetic diversity of the human hepatitis B virus. *Hepat. Res.*, 40: 14-30.
- 22- Khosrav, H .;Boroujeni, H. ; Mohammad , I. ; Sarrafzadegan, N. ; Sajjadi, F. ; Aghroun,M. ;Khosravi , A. ; Alikhasi, H. ; R afieian , M.and (2012) : Potato consumption and cardiovascular disease risk factors among Iranian population . International journal of food sciences and nutrition . Volume 63(8): 913-920 .
- 23- Lee, R.D and Nieman, D.C (1996) : Nutritional Assessment . 2nd Ed . Mosby, Missoun, USA .
- 24- Lopez De Leon A. and Rojkind M. (1985): A simple micromethod for collagen and total protein determination in formalin-fixed.
- 25- Logani, M. S. ; Chen, T. C. ; Tran, T. Le and Raffa, R. B. (2013): “Actions of Ginkgo Biloba Related to Potential Utility for the Treatment of Conditions Involving Cerebral Hypoxia,” Life Sciences, Vol. 67, No. 12, pp. 1389-1396. doi:10.1016/S0024-3205(00)00741-4
- 26- Lin, W.C, Lin WL. (2006): Ameliorative effect of Ganoderma lucidum on carbon tetrachloride-induced liver fibrosis in rats. World J Gastroenterol. 12(2):265-70.
- 27- Lattanzio, V. ; Kroon, P. A. ; Linsalata, V. amd Cardinali, A. (2009). Globe artichoke: a functional food and source of nutraceutical ingredients. J. Funct. Foods, 1, 131-144.
- 28- Llorach, R., ; Espin, J.C., ; Toma-Barberan, F.A., & Ferreres, F. (2002): Artichoke (*Cynara scolymus* L.) byproducts as a potential source

- of health-promoting antioxidant phenolics. *J. Agric. Food Chem.*, 50, 3458-3464.
- 29- Martinek RG. (1972): A rapid ultraviolet spectrophotometric lactic dehydrogenase assay. *Clin Chim Acta* 40: 91–99.
- 30- Nishikimi, M. ; Raz , V . and Yagi, K. (1972): The occurrence of superoxide anion in the reaction of reduced phenazine methosul fate and molecular oxygen. *Biochem and Bio . phys . Res . Comm.*, 46(2): 849 – 854 .
- 31- Mahboub, A. and Hawazen, A (2013): Protective Effect of *Gingo biloba* Extract on Carbendazim-Induced Hepatotoxicity in Albino Rats. *Food and Nutrition Sciences*, 4, 866-872
- 32- Masteikova, J. ; Muselik, J. ; Bernatoniene, R. and Ber- natoniene , R. (2007): “Antioxidative Activity of Ginkgo, Echinacea and Ginseng Tinctures,” *Medicina (Kaunas)*, Vol. 43, No. 4, pp. 306-309 .
- 33- Mahadevan , S. and Park, Y. (, 2008): “Multifaceted Therapeutic Benefits of *Ginkgo biloba* L.: Chemistry Efficacy, Safety and Uses,” *Journal of Food Science*, Vol. 73, No. 1, pp. 14-19.
- 34- Ohkawa , H. ; Ohishi , N . and Yagi , K. (1979): Assy for lipid peroxidation in animal tissue by thiobarbituric acid reaction . *Anal . Boichem .* , 95 : 351 – 358
- 35- Prins, H. and Loose , j. (1969): Glutathione . chapter 40 in : Biochemical methods in red cells genetics. Edited by J.J. Yuris . Academic press , N . Y . D . London : 126 – 129.
- 36- Qi, Y. ; Liu, Q. ; Li, J. and Chen, X. (2010): “Protective Effect of *Gingo biloba* Extract on Carbendazim-Induced Hepatotoxicity in Albino Rats. Vol. 35, No. 22, , pp. 3043-3047
- 37- Roy, S.E. (1970): Colorimetric determination of serum alkaline phosphatase. *Clin. Chem.*, 16: 431-432.
- 38- Reitman, S . and Frankel , S. (1957): Acolorimetic method for determination of serum glutamic oxaloacetic and g glutamic pyruvic transaminase. *Am . J. Clin . Pathol .* , 28: 60.
- 39- Saleem , T.S. ; Chetty, S.M. ; Ramkanth, S. ; Rajan, V.S. ;Kumar, K.M. and Gauthaman, K.(2010): Hepatoprotective herbs-a review. *Int. J. Res.Pharmaceut. Sci.*, 1: 1-5.
- 40- SPSS. (2008) : Statistical Package for Social Science, Computer Software, Ver.10, SPSS Company , London, UK.
- 41- Sundaresan, S. and Subramanian, P. (2008): Prevention of N-nitrosodiethylamine-induced hepatocarcinogenesis by S-allylcysteine. *Mol. Cell. Biochem.*; 310:209-214.
- 42- Shen, J. ; Wang, B. ; Zhao, J. ; Hou, T. ; Gao , J. and Xin, W. (1998): “Effects of EGb 761 on Nitric Oxide and Oxygen Free Radicals, Myocardial Damage and Arrhythmia in Ische-mia-Reperfusion

- Injury *in Vivo*,” *Biochimica et Biophysica Acta*, Vol. 1406, No. 3, pp. 228-236.
- 43- Stanilov, N.; Miteva, L.; Deliysky, T.; Jovchev, J. and Stanilova, S. (2010): Advanced colorectal cancer is associated with enhanced IL-23 and IL-10 serum levels. *Lab. Med.*; 41:159-163.
- 44- Wang, M., ; Simon, J. E. ; Aviles, I. ;He, K. ; Zheng, Q. & Tadmor, Y. (2003). Analysis of antioxidative phenolic compounds in artichoke (*Cynara scolymus* L.). *J. Agric. Food Chem.*, 51, 601-608.
- 45- Yang, Y. W. ; Su, M. C. ; Ng, C. L. ; Chang, Y. and Lu, K. T.(2005):
- 46- “Extract of *Ginkgo biloba* EGb 761 Facilitates Fear Conditioning Measured by Fear-Potentiated Startle,” *Neuroscience Letters*, Vol. 383, No. 1-2, pp. 145-150.
- 47- Yerram, R.B. (2011): Pharmacological studies on artichoke leaf extract -An edible herb of Mediterranean origin . *Journal of Pharmaceutical and Biomedical Sciences (JPBMS)*, Vol. 11, Issue 11
- 48- Zhang ,C. ; Zhu ,Y. ; Wan, J. ; Xu, H. ; Shi, H.and Lu , X. (2006 a): Effects of *Ginkgo biloba* extract on cell proliferation, cytokines and extracellular matrix of hepatic stellate cells. *Liver Int.* 26(10):1283-90.

التأثير الواقي لمستخلص الجنكو بيلوبا (EGb 761) والخرشوف ضد سرطان الكبد الناجم عن برابع كالوريد الكربون فى ذكور الفئران

د/ هالة محمد علي وهبة

استهدف هذا البحث دراسة التأثير الواقي وفحص آليات العمل لمستخلص الجنكو بيلوبا (EGb 761) والخرشوف ضد سرطان الكبد الناجم عن برابع كالوريد الكربون فى ذكور الفئران. فتم توزيع عدد ٣٠ من ذكور الفئران البالغة بطريقة عشوائية إلى ٥ مجموعات كل منها ٦ فئران. المجموعة الأولى كانت ضابطة سالبة (فئران غير مصابة) والمجموعة الثانية ضابطة موجبة (فئران مصابة)، والمجموعات الثالثة والرابعة والخامسة كانت فئران مصابة بالسرطان وتم إعطائها عن طريق الفم مستخلص الجنكو بيلوبا (EGb 761) و ٢٠ % الخرشوف وخليط منهما على التوالى لمدة ٨ اسابيع. وتم إحداث الإصابة بالسرطان بحقن الفئران فى التجويف البريتونى بجرعة مفردة (٢. مجم / ١٠٠كجم) لمدة ثلاثين يوم . وفى نهاية فترة التجربة تم تجميع عينات من الدم لعمل التحليلات البيوكيميائية فى المصل ، وتم أخذ نصف الأكياد لقياس دلائل أكسدة الدهون ونشاط الإنزيمات المضادة للأكسدة (سوبر أوكسيد دثميوتيز - جلوتاثيون بيروكسيديز - كاتاليز) فى نسيج الكبد. واستخدم النصف الآخر لإجراء الفحص الهستوباثولوجى للكبد. وأظهرت النتائج أن إعطاء مستخلص الجنكو بيلوبا (EGb 761) والخرشوف عن طريق الفم لمدة ٨ اسابيع أدى إلى نقص معنوى فى مستوى إنزيمات الكبد المرتفعة (اسبرتات أمينو ترانسفيريز، الانين أمينو ترانسفيريز والكالين فوسفاتيز) بينما أدى إلى زيادة بروتينات الدم. وأدى أيضا إلى نقص معنوي فى دلائل سرطان الكبد بالمصل بينما أدى إلى زيادة نشاط الإنزيمات المضادة للأكسدة فى نسيج الكبد. وأظهر الفحص الهستوباثولوجى وجود تحسن أو إختفاء التغيرات المرضية المحدثة برابع كالوريد الكربون فى نسيج كبد الفئران. ودلت النتائج على أن مستخلص الجنكو بيلوبا (EGb 761) والخرشوف لهما تأثير واقى ضد سرطان الكبد. وأشارت النتائج إلى أن آليات عمل مستخلص الجنكو بيلوبا (EGb761) والخرشوف كمضاد للسرطان قد تكون عن طريق منع أكسدة الدهون بنسيج الكبد وزيادة نشاط الإنزيمات المضادة للأكسدة وإحداث موت مبرمج فى خلايا الكبد. وتوصى هذه الدراسة أن شرب مستخلص الجنكو بيلوبا (EGb 761) والخرشوف قد يكون مفيدا للمرضى الذين يعانون من سرطان الكبد.